

8-18-2017

Neurological Impact of Zinc Excess and Deficiency In vivo

Ronald Bartzatt

University of Nebraska at Omaha, rbartzatt@unomaha.edu

Follow this and additional works at: <http://digitalcommons.unomaha.edu/chemfacpub>

 Part of the [Chemistry Commons](#)

Recommended Citation

Bartzatt, Ronald, "Neurological Impact of Zinc Excess and Deficiency In vivo" (2017). *Chemistry Faculty Publications*. 41.
<http://digitalcommons.unomaha.edu/chemfacpub/41>

This Article is brought to you for free and open access by the Department of Chemistry at DigitalCommons@UNO. It has been accepted for inclusion in Chemistry Faculty Publications by an authorized administrator of DigitalCommons@UNO. For more information, please contact unodigitalcommons@unomaha.edu.





Neurological Impact of Zinc Excess and Deficiency ***In vivo***

Ronald Bartzatt^{1*}

¹*Durham Science Center, University of Nebraska, 6001 Dodge Street, Omaha, Nebraska 68182, USA.*

Author's contribution

The sole author designed, analyzed and interpreted and prepared the manuscript.

Article Information

DOI: 10.9734/EJNFS/2017/35783

Mini-review Article

Received 29th July 2017
Accepted 14th August 2017
Published 18th August 2017

ABSTRACT

Zinc is an essential mineral that can cause pathological effects whether in excess or deficiency. Zinc is a component for over 250 enzymes and is required for cell growth, cell division, and cell function. Zinc is found in muscle and bones, with the prostate, liver, skin, and kidney having detectable levels of zinc. However, zinc present in excess or deficiency can cause significant pathology in patients that include deleterious effects neurologically. Zinc in excess *in vivo* can cause focal neuronal pathology, while zinc deficiency can bring about mental lethargy, neuropsychiatric disorders, and reduced nerve conduction. Zinc is assimilated within the body by oral ingestion, dermal exposure, and pulmonary inhalation. Although not generally viewed as a cause of cancer, studies suggest that zinc is associated with progression of prostate malignancy. Toxic levels of zinc have been shown to induce lethargy, neurotoxicity, and gliotoxicity. High levels of zinc causes neuronal death in cortical cell tissue culture. Zinc is known to accumulate following the death of neurons in global ischemia. Therefore, zinc deficiency or excess is of significant clinical concern.

Keywords: Zinc; toxic metals; vitamins; minerals.

1. AN ESSENTIAL MINERAL

Zinc is an element found in-group 12 of the periodic chart and is a transition metal (any element in the d-block of the periodic table). Zinc is an essential mineral, one of a total of 16, which

includes [1]: calcium, phosphorus, potassium, sulfur, sodium, chloride, magnesium, iron, zinc, copper, manganese, iodine, and selenium, molybdenum, chromium, and fluoride. There are two types of minerals: macro-minerals and trace minerals. Macro-minerals are minerals required

*Corresponding author: Email: rbartzatt@unomaha.edu;

for normal health in larger amounts than trace minerals. Macro-minerals include calcium, phosphorus, magnesium, sodium, potassium, and chloride. Zinc is an important mineral for many organisms and is known to be a component of more than 250 enzymes and a large number of proteins [1]. Therefore, zinc is profoundly important for normal human health.

Of all the zinc found in the human body, almost 90% are located in the bones and muscles of individuals [1]. The oral consumption of zinc is followed by absorption in the small intestines, followed by dissemination throughout the body, carried by serum where it is bound to proteins [1].

Having noted the importance of zinc for human nutrition and health, it is necessary to address the reality that zinc deficiency or significant excess in the body results in pathological conditions. Zinc can play a strong role in neuronal death and participate in toxic events on the cellular level [1]. Zinc is believed to be associated with the regulation of apoptosis (death of cells that occurs as a normal and controlled part of an organism's development) at the cellular level [1].

2. ZINC IN THE HUMAN BODY

Almost 90% of the total amount of zinc found in the body (up to 3 grams total) is located in the bones and muscles [1]. Zinc is also found in the gastric intestines, brain, pancreas, skin, stomach, and kidney (see Fig. 1) [2,3]. Once in the serum, zinc is bound to proteins such as transferrin, α -microglobulin, and albumin [1].

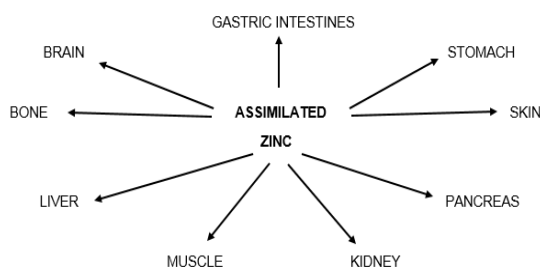


Fig. 1. Disposition of zinc in the human body. Zinc is found in numerous organs, including the brain, bones and muscle

Within the cell itself, it is generally accepted that 50% of zinc present will be in the cytosol with somewhere from 30% to 40% contained in the nucleus [4]. The remaining balance is localized in

the membranes [4]. In these locations, zinc plays an important role in nucleic acid and protein metabolism, as well as cell growth, function, and cell division [5]. Interestingly, the cellular zinc component is thought to play some role in homeostatic control that avoids the assimilation of excess zinc [1].

3. ZINC ASSIMILATION, NEUROLOGICAL AND OTHER EFFECTS

The assimilation of zinc into the human body can be accomplished by three pathways. These three pathways are inhalation, oral ingestion, and absorption through skin [6]. The eventual effects, as a result of each type of assimilation, will be depend upon specific portions of the body within these pathways [6].

Although there are pathological results of excessive uptake or deficiency, the oral ingestion of adequate zinc in nutrition is important for normal health [1]. The oral consumption of excessive amounts of zinc will quickly bring about noticeable nausea, vomiting, abdominal pain, and eventual anemia [7]. Subsequent effects originating from the central nervous system will include lethargy (pathological state of unresponsiveness, inactivity, and dizziness) [7]. Further studies have shown that excessive oral ingestion will bring about overt symptoms such as fatigue and lethargy [8].

Pulmonary inhalation of continuous/excessive amounts of zinc is shown to cause pathological issues. Inhalation of zinc in the form of industrial originated zinc oxide will cause shakes and chills, sometimes referred to as metal fume fever or zinc shakes (illness primarily caused by exposure to chemicals such as zinc oxide) [9]. Galvanization (applying zinc to other metals to prevent rust) is a process that can result in aerial exposure of zinc [1]. Particle sizes of less than 1 micrometer can effectively introduce troubling levels of zinc into the body, with these exposures primarily originating from industrial settings [10]. Symptoms noticeable include fatigue, nausea, fever, chest pain, cough, dyspnea (difficult breathing), and muscle soreness [11].

Concerning assimilation through the dermal layers, it is known that zinc is a common component of various topical treatments of various conditions, including of wounds that cause breaks within the skin [12]. However, the extent of zinc absorption is influenced by the pH of the skin, chemical speciation, and amount of

zinc applied from the medicament [13]. Overall, it is generally accepted that exposure to zinc through dermal pathways does not constitute a significant pathological risk [1].

Interestingly, the excess exposure to zinc derived from denture adhesives can induce copper deficiency leading to neurological symptoms involving walking and balance [14]. Unfortunately, recovery from these neurological symptoms looks to be limited in extent and efficacy [14]. Alarmingly, other investigators have reported even more severe results of excess zinc exposure from denture fixative creams that include serious neurological effects such as degeneration of the spinal cord, crippling nerve damage such as human swayback disease, as well as bone marrow suppression [15]. Swayback disease caused by excess zinc that induces a copper deficiency brings about neurological manifestations, including myelopathy (disease of the spinal cord), a spastic gait, and prominent sensory ataxia (loss of control) [15]. Copper deficiency, induced by zinc exposure in denture creams is shown to cause serious neurological disease [16].

Therefore, the assimilation of excess zinc as well as the deficiency thereof- induces various significant neurological related health maladies, these summarized in Table 1. These include lethargy, effects upon focal ability, and psychiatric conditions [1]. There are other notable health related risks associated with zinc assimilation.

Certain metals have been associated with carcinogenicity (i.e. nickel, chromium) but zinc is generally not accepted to be a causative factor for cancer [1]. However, other studies of prostate adenocarcinoma, and particularly those monitoring the level of zinc in the surrounding tissues, indicate the potential involvement of zinc in the progression of prostate malignancy [17,18].

Even though there are homeostatic mechanisms preventing zinc from achieving a level in the brain that would cause pathological results, there

are cases where neurological symptoms follow zinc intoxication [1]. One case relates how a young male child induced lethargy and focal neurological reduction following 72 hours after ingesting as much as 12 grams of metallic type zinc [19]. Previous studies have shown that zinc can function as a neuromodulator [20,21]. Other studies have demonstrated that zinc within the body could be a rapid and potent neurotoxin, as well as a gliotoxin [22,23,24]. Other substantial neural health issues will now be discussed.

Previous studies have shown that an exposure to zinc at a level of 300 μ M to 600 μ M, for as little as 15 minutes, can induce extensive neuronal death in tissue culture of cortical cells [25]. Zinc has been shown to be active in neuronal damage, participates in action during membrane depolarization following acute brain injury to increase its neurotoxicity [26]. This membrane depolarization causes an increase effect of zinc to act as a neurotoxin [27].

Other studies have described zinc as a necessary component of excito-toxic cascade following seizures, ischemia (inadequate blood supply to an organ, especially the heart muscles), and head related trauma [28,29].

Damage to the brain regions out of broad ischemia to hippocampal CA1, thalamus, neocortex, and striatum have shown zinc accumulation among dying or dead neurons [30]. This event has also been shown to occur in the hippocampal hilar region [30]. The fact that this event described above can be prevented by intraventricular injection of zinc chelator calcium-EDTA (Edetate Calcium Disodium) supports the assertion that zinc accumulation leads to neuronal cell death [31].

Previous studies have associated zinc to an oxidative stress type induction to neuron cell damage [32]. Inclusive is a study showing zinc-induced neuron cell death occurring with the increased levels of reactive oxygen species within neurons [33]. Seen as a support for this scenario of zinc action on neurons, the zinc-induced cell death is decreased by introduction of anti-oxidant agents [34].

Table 1. Effects caused by zinc deficiency and substantial excessive presence

Condition/Pathology	
Zinc deficiency	Zinc substantial excess
Reduction of nerve conduction	Mental related lethargy
Lethargy due to mental effects	Reduction of focal activity
Pathology of neurosensory ability	
Pathology of psychiatric ability	

A zinc-induced apoptosis event in neurons can take place by a pathway triggering caspase activation (and apoptosis) by induction of p75^{NTR} associated death executor and neurotrophin receptor p75^{NTR} [35,36].

The release of intracellular zinc will initiate neuronal apoptosis [37,38], with accompanied cell swelling and destruction of intracellular organelles [39,37]. Altogether, these studies suggest that zinc-initiated neuronal cell death encompasses both apoptotic and necrotic mechanisms (cell injury, which results in the premature death of cells) [29].

Previous studies have shown the likelihood that zinc is involved in certain neurodegenerative diseases [40]. The improper regulation of zinc homeostasis and zinc may play a substantial role for the onset and progression of Alzheimer's disease [40].

Other unfortunate cases include the fatal accidental over dose of zinc to a neonate following confusion of amounts of micrograms to milligrams [41]. A study conducted in Nepal showed that zinc phosphide occurred in 6.5% of all poison cases occurring in 2004 [42]. Also, acute intravenous zinc poisoning occurs from poor administration of parenteral nutrition with intravenous injection [43].

In addition to pathological conditions described above, symptoms from zinc deficiency such as growth retardation, skin changes, poor appetite, mental lethargy, taste abnormalities, slow wound healing have been noted in even moderate zinc deficiency [44]. The condition of zinc deficiency is aggravated by low dietary intake, alcohol abuse, malabsorption, and chronic renal disease [1,44]. Zinc deficiency is seen to be widespread and has a destructive impact on neuronal development, as well as immunity of the patient [1].

Therefore, it is seen that endogenous zinc can be substantially involved with cytotoxic actions in individual cells. Studies have shown that zinc has a notably activity in cell death occurring in the brain [1]. However, zinc is considered to be one of the essential minerals for human health. The dual role that zinc plays in human health and clinical pathology deserves further study. To understand the role zinc plays in pathological events is important, in order to determine a remedial course of treatment. Therefore, the investigation will continue and elucidate important facets of zinc in the human body.

4. CONCLUSION

Endogenous zinc is known to have important involvement within cytotoxic activity within individual cells. Zinc excess is shown to induce lethargy and focal neuronal reduction. Zinc deficiency has been shown to induce lethargy, neurosensory pathology, neuropsychiatric disorders, and reduction of nerve conduction. Oral ingestion of toxic levels of zinc will produce symptoms of dizziness and lethargy. The inhalation of zinc can bring about shaking, fatigue, and fever. Although zinc acts as a neuromodulator, endogenous zinc can be a potent and rapid neurotoxin. At 300 μ M levels, zinc will extensively destroy cortical cells in tissue culture. Neurons exposed to zinc will initiate apoptosis. The activity of zinc in the human body has significant implications for normal health. Zinc in excess or deficit will cause pathological conditions which should be rapidly diagnosed by clinicians. Further study of the biological activity of zinc is warranted.

COMPETING INTERESTS

Author has declared that no competing interests exist.

REFERENCES

1. Plum LM, Rink L, Haase H. The essential toxin: impact of zinc on human health. *Int J Environ Res Public Health*. 2010;7:1342-65.
2. Bentley PJ, Grubb BR. Experimental dietary hyperzincemia tissue disposition of excess zinc in rabbits. *Trace Elem Med*. 1991;8:202-7.
3. He LS, Yan XS, Wu DC. Age-dependent variation of zinc-65 metabolism in LACA mice. *Int J Radiat Biol*. 1991;60:907-16.
4. Llobet JM, Domingo JL, Colomina MT, Mayaya E, Corbella J. Subchronic oral toxicity of zinc in rats. *Bull Environ Contam Toxicol*. 1988;41:36-43.
5. Vallee BL, Falchuk KH. The biochemical basis of zinc physiology. *Physiol Rev*. 1993;73:79-118.
6. Toxicological Profile for Zinc. Agency for Toxic Substances and Disease Registry Division of Toxicology and Environmental Medicine: Atlanta, GA, USA; 2005.
7. Porea TJ, Belmont JW, Mahoney DH. Zinc-induced anemia and neutropenia in

- an adolescent. *J Pediatr.* 2000;136:688-690.
8. Fosmire GJ. Zinc toxicity. *Am J Clin Nutr.* 1990;51(2):225-7.
 9. Pettilla V, Takkunen O, Tukiainen P. Zinc chloride smoke inhalation: A rare cause of severe acute respiratory distress syndrome. *Intensive Care Med.* 2017; 26(2):215-17.
 10. Vogelmeier C, Konig G, Bencze K, Fruhmann G. Pulmonary involvement in zinc fume fever. *Chest.* 1987;92:946-48.
 11. Rohrs LC. Metal-fume fever from inhaling zinc oxide. *AMA Arch Ind Health.* 1957; 16:42-47.
 12. Agren MS, Krusell M, Franzen L. Release and absorption of zinc from zinc oxide and zinc sulfate in open wounds. *Acta Dermato-Veneriol.* 1991;71:330-33.
 13. Agren MS. Percutaneous absorption of zinc from zinc oxide applied topically to intact skin in man. *Dermatologica.* 1990; 180:36-9.
 14. Doherty K, Conner M, Cruickshank R. Zinc-containing denture adhesive: A potential source of excess zinc resulting in copper deficiency myelopathy. *Br Dent J.* 2011;210(11):523-5.
 15. Shammaa Y, Rodgers J. Denture fixative cream and the potential for neuropathy. *Dent Update.* 2012;39(8):575-7.
 16. Nations SP, Boyer PJ, Love LA, Burritt MF, Butz JA, Wolfe GI, et al. Denture cream: an unusual source of excess zinc, leading to hypocupremia and neurologic disease. *Neurology.* 2008;71(9):639-43.
 17. Costello LC, Franklin RB. Novel role of zinc in the regulation of prostate citrate metabolism and its implications in prostate cancer. *Prostate.* 1998;35:285-96.
 18. Habib FK. Zinc and the steroid endocrinology of the human prostate. *J Steroid Biochem.* 1978;9:403-7.
 19. Murphy JV. Intoxication following ingestion of elemental zinc. *JAMA.* 1970;212:2119-2120.
 20. Colvin RA, Fontaine CP, Laskowski M, Thomas D. Zn²⁺ transporters and Zn²⁺ homeostasis in neurons. *Eur J Pharmacol.* 2003;479:171-185.
 21. Frederickson CJ, Bush AI. Synaptically released zinc: Physiological functions and pathological effects. *Biometals.* 2001;14: 353-366.
 22. Cuajungco MP, Lees GJ. Zinc and Alzheimer's disease: Is there a direct link? *Brain Res Rev.* 1997;23:219-36.
 23. Cuajungco MP, Lees GJ. Zinc metabolism in the brain: Relevance to human neurodegenerative disorders. *Neurobiol Disease.* 1997;4:137-69.
 24. Frederickson CJ, Suh SW, Silva D, Thompson RB. Importance of zinc in the central nervous system: The zinc-containing neuron. *J Nutr.* 2000;130: 1471S-1483S.
 25. Yokoyama J, Koh J, Choi DW. Brief exposure to zinc is toxic to cortical neurons. *Neurosci Lett.* 1986;71:351-55.
 26. Siesjo BK. Basic mechanisms of traumatic brain damage. *Ann Emerg Med.* 1993;22: 959-69.
 27. Fredrickson CJ, Koh JY, Bush AI. The neurobiology of zinc in health and disease. *Nat Rev Neurosci.* 2005;6:449-62.
 28. Choi DW, Koh JY. Zinc and brain injury. *Annu Rev Neurosci.* 1998;21:347-75.
 29. Weiss JH, Sensi SL, Koh JY. Zn(2+): A novel ionic mediator of neural injury in brain disease. *Trends. Pharmacol Sci.* 2000;21:395-401.
 30. Koh JY, Suh SW, Gwag BJ, He YY, Hsu CY, Choi DW. The role of zinc in selective neuronal death after transient global cerebral ischemia. *Science.* 1996;272: 1013-1016.
 31. Suh SW, Chen JW, Motamedi M, Bell B, Listiak K, Pons NF, et al. Evidence that synaptically-released zinc contributes to neuronal injury after traumatic brain injury. *Brain Res.* 2000;852:268-73.
 32. Kim EY, Koh JY, Kim YH, Sohn S, Joe E, Gwag BJ. Zn²⁺ entry produces oxidative neuronal necrosis in cortical cell cultures. *Eur J Neurosci.* 1999;11:327-23.
 33. Sensi SL, Yin HZ, Weiss JH. Glutamate triggers preferential Zn²⁺ flux through Ca²⁺ permeable AMPA channels and consequent ROS production. *Neuroreport.* 1999;10:1723-27.
 34. Seo SR, Chong SA, Lee SI, Sung JY, Ahn YS, Chung KC, et al. Zn²⁺-induced ERK activation mediated by reactive oxygen species causes cell death in differentiated PC12 cells. *J Neurochem.* 2001;78:1878-88.
 35. Park JA, Lee JY, Sato TA, Koh JY. Co-induction of p75NTR and p75NTR-associated death executor in neurons after zinc exposure in cortical culture or transient ischemia in the rat. *J Neurosci.* 2000;20:9096-9103.
 36. Mukai J, Hachiya T, Shoji-Hoshino S, Kimura MT, Nadano D, Suvanto P, et al.

- NADE, a p75NTR-associated cell death executor, is involved in signal transduction mediated by the common neurotrophin receptor p75NTR. *J Biol Chem.* 2000;275:17566-17571.
37. Kim YH, Kim EY, Gwag BJ, Sohn S, Koh JY. Zinc-induced cortical neuronal death with features of apoptosis and necrosis: Mediation by free radicals. *Neuroscience.* 1999;89:175-182.
 38. Lobner D, Canzoniero LM, Manzerra P, Gottron F, Ying H, Knudson M, et al. Zinc-induced neuronal death in cortical neurons. *Cell Mol Biol.* 2000;46:797-806.
 39. Broun ER, Greist A, Tricot G, Hoffman R. Excessive zinc ingestion: A reversible cause of sideroblastic anemia and bone marrow depression. *JAMA.* 1990;265:1441-1443.
 40. Devirgiliis C, Zalewski PD, Perozzi G, Murgia C. Zinc fluxes and zinc transporter genes in chronic diseases. *Mutat Res.* 2007;622:84-93.
 41. Grissinger M. A fatal zinc overdose in a neonate: Confusion of micrograms with milligrams. *P T.* 2011;36(7):393-409.
 42. Paudyal BP. Poisoning: Pattern and profile of admitted cases in a hospital in central Nepal. *JNMA J Nepal Med Assoc.* 2005;44-159:92-6.
 43. Polson DJ, tattersall RN. *Clinical Toxicology.* London: Pitman; 1969.
 44. Prasad AS. Clinical manifestations of zinc deficiency. *Annu Rev Nutr.* 1985;5:341-63.

© 2017 Bartzatt; This is an Open Access article distributed under the terms of the Creative Commons Attribution License (<http://creativecommons.org/licenses/by/4.0>), which permits unrestricted use, distribution, and reproduction in any medium, provided the original work is properly cited.